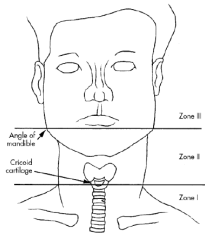
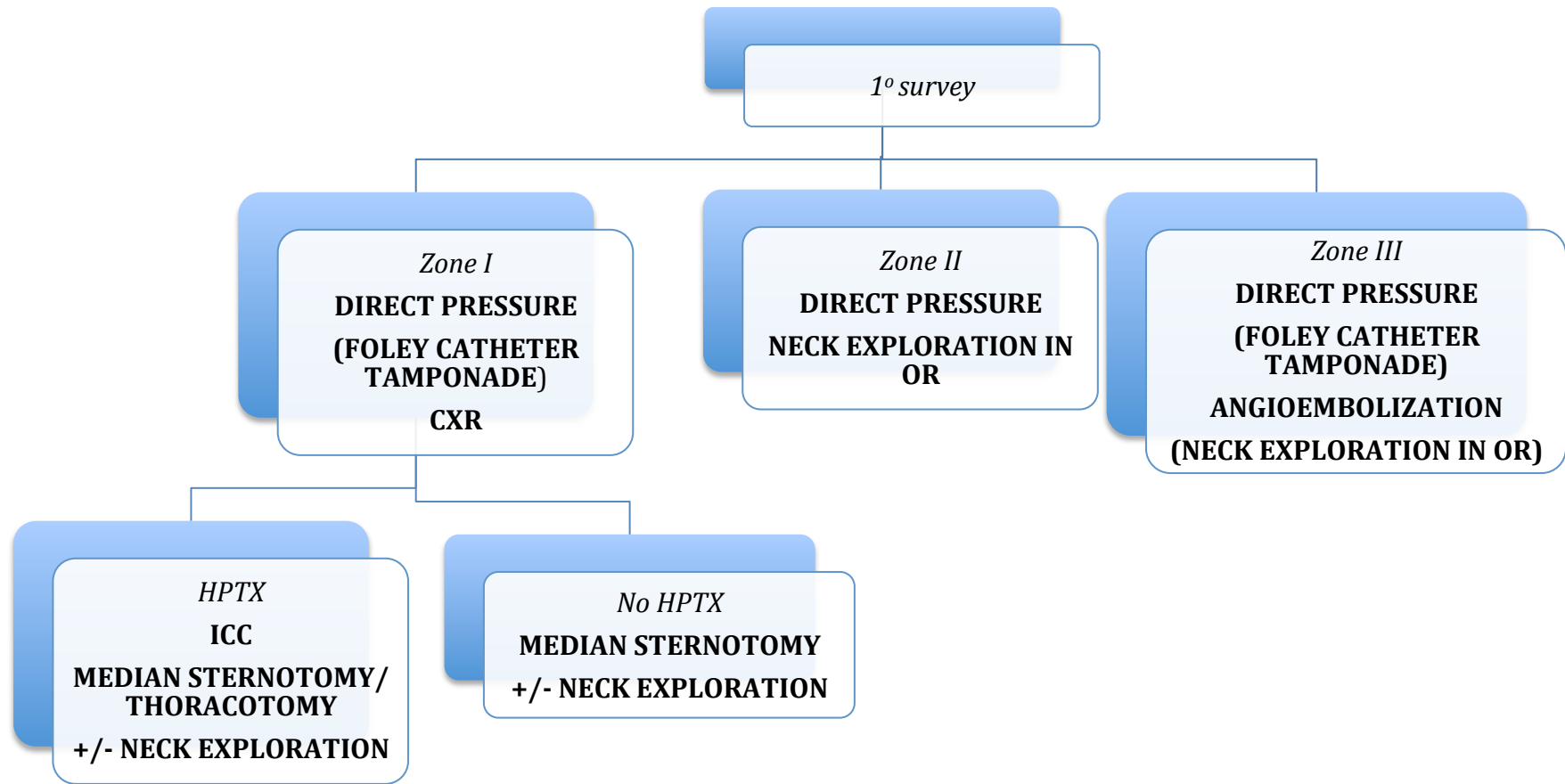
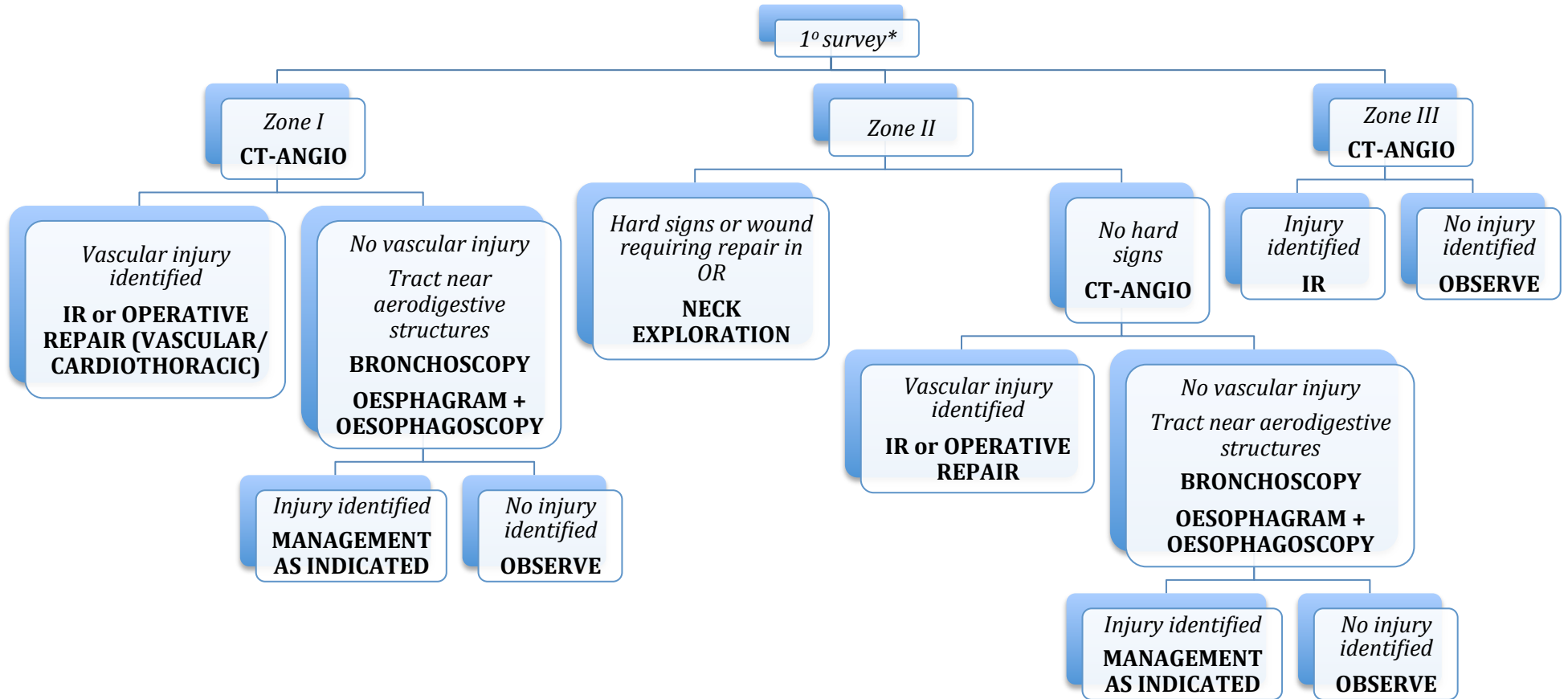


PENETRATING NECK INJURY – HAEMODYNAMICALLY COMPROMISED



PENETRATING NECK INJURY – HAEMODYNAMICALLY NORMAL



- Hard signs = active bleeding, expanding/pulsatile haematoma, bruit/thrill, refractory shock, air bubbling through wound, massive haemoptysis, massive haematemesis
- Soft signs aerodigestive injury = hoarseness, stridor, subcutaneous emphysema, odynophagia, dysphagia

